JCUMSA

CLINICAL SKILLS GUIDE

COMPILED FOCUSED EXAMS

2017

Authors: Dr Ellen West & Dr. Mai-Ing Koh

JAMES COOK UNIVERSITY
MEDICAL STUDENTS ASSOCIATION

Hi everyone,

On behalf of the JCU Medical Students Association (JCUMSA) we would like to offer you all a very warm welcome to the clinical years of medicine. Congratulation on getting through the pre-clinical years and we hope that you are looking forward to the excitement of working and being involved within the hospital system.

The JCUMSA Clinical Skills Guide has been designed to get you the best start to the clinical years of medicine in JCU. This handbook is a compilation of focused examination thought to be necessary for a competent 4th year Medical student. Examinations have been created from both the notes provided by JCU COMD's Clinical School in conjunction with Tally O'Connor's Clinical Examination: A systematic Guide. I hope this handbook can help ease your transition into clinical medicine.

I would like to acknowledge Dr. Ellen West & Dr. Mai-Ing Koh, JCU Alumni Class of 2014 for their hard work and efforts in bringing this document together. I would also like to acknowledge the JCUMSA Executive and the JCUMSA Academic Subcommittee of 2017 for their continued hard work and dedication for the improvement and advancement of the of the student body's experience whilst their time in JCU medicine and for their help in compilation of this document.

JCUMSA is always here to help and you can find us at www.jcumsa.org.au or Facebook/Instagram/Snapchat. We are happy to answer any questions you might have!

Good luck and enjoy the rest of your journey! If I can be of any assistance, please don't hesitate to ask. All the best!

Ritvik Gilhotra
Academic Vice President, JCUMSA 2017

YOUR 2017 ACADEMIC TEAM!

Ritvik Gilhotra - Academic VP

Year 1



Eusebio Goncalves

Vidhushan Paheerathan

Year 2

Daniel Mahon

Aimee Harbottle

Year 3

Julian Pecora

Shivin Moza

Year 4

Matthew Riggs, TSV

Anusheh Mubeen, TSV

Obert Xu, CNS

Jonathan Wiener, CNS

Year 5

Britt Van Der Lugt, TSV

Pauline Lau, CNS

Shivam Khanna, MKY

Femy Koratty, DWN

Year 6

Diane Quach, TSV



Sarah Adamson, CNS

Georgina Spalding, MKY

Syahira Johan, DWN

YOUR 2017 EXECUTIVE

Rituik Gilhotra
Academic VP

Satyen Hargovan
President

Katherine Rimmer
Events VP

Shalisa Maisrikrod
Sponsorship Officer

Maisha Jamali
Secretary

Shaurya Jhamb
Treasurer

James Coventon
Community and Wellbeing Officer

Lisa Fernandez
Publications Officer

Reece Tso
AMSA Liaison Officer

JCU MSA

CONTENTS PAGE

- *Upper Limb Summary*

Lower Limb

- *Lower Limb Summary*

Cranial Nerves

Cerebellar Disease

Parkinson's

MUSCULOSKELETAL

Rheumatoid Arthritis

Focussed Shoulder

Focussed Knee

GALS Screening Test

RENAL

Chronic Renal Failure

OTHER

Breast

Pelvic Examination

Inguinal/Hernia Examination

Mini Mental State Examination

Systems Review

History Boxes from Talley

INTRODUCTION

How to Use the Examination Sheets

Each focused examination will be found under its corresponding system.

At the start of each examination you will see the following:

INTRODUCE	EXPLAIN	CONSENT	WASH HANDS

These are four critical points that you will be marked on when entering any OSCE station.

1. Introduce – introduce yourself to the patient and obtain simple consent
   - 'Good morning, my name is XYZ. I am a fourth year medical student, is it alright if I perform a XXX examination on you today?'
2. Explain – explain briefly what the examination will entail (this helps with obtaining informed consent)
   - 'So this will just consist of me mainly checking your heart and having a listen to your heart sounds as well as having a look for other related signs on your body'
3. Consent – after explaining the procedure you can obtain informed consent
   - 'Is this alright with you?'
4. Wash hands – easy marks!! Don't forget this one
   - Remember, you can start general inspection whilst waiting for the alcohol gel to dry

Positioning the Patient

Before you proceed, it's important to position the patient and remove clothing that may impede general inspection (ie. For respiratory examination remove the shirt so you can see accessory muscles and ribs)

General Inspection

It's a good idea to have your own spiel that you can say when you begin general inspection – this will allow you time to think about what sort of focused examination you will be required to perform.

We haven't included these basic inspections in some examination sheets as they should ideally be used for every single one. Here is an example of what you could say:

'*On general inspection, the patient is sitting comfortably in a chair. They appear alert and well, and are of a normal body habitus*'

Vital Signs

REMEMBER to get your vital signs before you jump into examining the patient – in most OSCE stations you will be expected to measure your own pulse and respiratory rate (the examiner should stop you if this is not required).
State what you are looking for when asking the examiner for a vital sign: 'blood pressure to check for hypertension', 'respiratory rate to look for tachypnoea

CARDIOVASCULAR EXAMINATION

MYOCARDIAL INFARCTION

INTRODUCE	EXPLAIN	CONSENT	WASH HANDS

Position: patient lying on bed at 45°

General Inspection

- Unwell/distressed
- Body habitus (obese)
- Diaphoretic, anxious (angor animi)
- Restless
- Signs of cyanosis

Vital Signs

- Palpate radial pulse – sinus tachycardia, atrial fibrillation, ventricular tachycardia, heart block
- BP – hypertensive/hypotensive
- RR – tachypnoea
- O_2 sats, temperature

Hands

- Warm/cool, dry/sweaty
- Peripheral cyanosis
- CRT

Face

- Peripheral and central cyanosis
- Fundoscopy – Keith Wagener retinal changes hypertension

Neck

- JVP (raised, Kussmaul's sign)
- Carotid pulse

Chest

- Inspection: scars, abnormal pulsations, prominent veins, pacemaker
- Palpation: apex beat (dyskinetic), heaves, thrills
- Auscultation: heart sounds – S3, S4, ↓ intensity heart sounds, transient apical mid-systolic or late systolic murmur, pericardial friction rub

Legs

- Peripheral cyanosis
- CRT
- Peripheral pulses

CARDIOVASCULAR EXAMINATION

INFECTIVE ENDOCARDITIS

INTRODUCE EXPLAIN CONSENT WASH HANDS

Position: patient lying on bed at 45°

General Inspection
- Body habitus (weight loss)
- Fatigue, dyspnoea, evidence fever
- Pallor, plethora, cyanosis
- Dyspnoea

Vital Signs
- Palpate radial pulse – sinus tachycardia, low volume
- BP – hypertensive
- RR – tachypnoea
- Temp – febrile

Hands
- Warm/cool, dry/sweaty
- Pallor palmar creases, Janeway lesions, Osler's nodes
- Splinter haemorrhages, clubbing, peripheral cyanosis
- CRT

Face
- Eyes: conjunctival pallor, scleral jaundice, conjunctival haemorrhages & fundoscopy (Roth spots)
- Mouth: peripheral and central cyanosis, mucosal petechiae

Neck JVP and carotids

Chest
- Inspection: scars, abnormal pulsations, prominent veins, pacemaker
- Palpation: apex beat, heaves, thrills
- Auscultate: heart sounds

Posterior
- Palpation: sacral oedema
- Percussion: lung bases (dull)
- Auscultation: lung bases (bibasal crackles), crackles & wheeze throughout lung fields (pulmonary oedema)

Abdomen
- Palpation: hepatomegaly, splenomegaly, scrotal oedema
- Percussion: ascites

Legs
- Pedal oedema, peripheral cyanosis
- CRT
- Peripheral pulses

CARDIOVASCULAR EXAMINATION

HEART FAILURE

INTRODUCE	EXPLAIN	CONSENT	WASH HANDS

Position: patient lying on bed at 45°

General Inspection
- Body habitus (cardiac cachexia, signs of thyrotoxicosis)
- Tachypnoea
- Pallor, cyanosis

Vital Signs
- Palpate radial pulse – sinus tachycardia, AF, low volume pulse/low pulse pressure, pulsus alterans
- BP – hypotension
- RR – tachypnoea (↑ pulmonary pressure)
- O_2 sats, temperature

Symptoms

LVF: exertional dyspnoea, orthopnoea, paroxysmal nocturnal dyspnoea, cough

RVF: ankle, sacral and abdominal swelling, anorexia and nausea

Hands
- Warm/cool, dry/sweaty
- Peripheral cyanosis
- CRT

Face
- Mitral facies
- Conjunctival pallor
- Peripheral and central cyanosis

Neck
- JVP – positive hepatojugular reflex
- Carotid pulse

Chest
- Inspection: scars, abnormal pulsations, prominent veins, pacemaker
- Palpation: apex beat (displaced, dyskinetic, palpable gallop rhythm), heaves, thrills
- Auscultation: heart sounds – S3, mitral regurgitation, aortic regurgitation, aortic stenosis

Posterior
- Palpation: sacral oedema
- Percussion: lung bases (dull)
- Auscultation: bibasilar crackles, crackles and wheeze throughout lung fields (pulmonary oedema)

Abdomen
- Palpation: hepatomegaly, scrotal oedema
- Percussion: ascites

Legs
- Peripheral cyanosis
- Pedal oedema, peripheral pulses
- CRT

CARDIOVASCULAR EXAMINATION

HYPERTENSION

INTRODUCE	EXPLAIN	CONSENT	WASH HANDS

Position: patient lying on bed at 45°

General Inspection

- Body habitus (obese); any signs of metabolic syndrome/secondary causes (Cushing Syndrome)
- Orientated to person time place
- Facial drooping or body asymmetry suggestive of CVA

Vital Signs

- HR – tachycardia
- BP - ↑ (rise in diastolic pressure on standing in pts w essential HTN)
- RR & Temperature

Hands

- Pulse – radial-radial delay
- CRT
- Oedema

Face

- Eyes: xanthelasma, fundoscopy for hypertensive retinopathy
- Neck: swelling (Graves' disease), JVP, carotid pulse, listen for carotid bruits

Chest (CVS)

- Inspection: any deformity, scars, visible pulsations, visible apex beat
- Palpation: heaves, thrills, palpable intercostalpulses, palpable apexbeat
- Auscultation: S4 gallop rhythm (↓LV compliance), accentuated S2 HS, aortic insufficiency murmur
- RS: signs of CCF (dull bases and bibasal crepitations)

Abdomen (patient lying down, one pillow beneath head)

- Inspect: organomegaly, abnormal pulsations, distension
- Palpate: ballot kidneys (enlarged in ADPKD), abdominal aorta(aneurysm)
- Percuss: fluid shift (ascites)
- Auscultate: venous hum, renal bruit, hepatic bruit

***I would also do a DRE and genital examination*

Legs

- Signs of PVD: shiny atrophic skin with hair loss
- Femoral pulses – delayed, symmetrical; other peripheral pulses
- Calf tenderness
- CRT
- Auscultate for femoral bruit

Hypertensive Retinopathy

Grade I – silver wiring and vascular tortuosities

Grade II – Grade I + AV nipping

Grade III – Grade II + cotton wool spots and flame-haemorrhages

Grade IV – Grade III + papilloedema

Target Organs

BV – atherosclerosis, CAD, CVD, PVD

CNS – cerebrovascular haemorrhage/ infarction

Retina – retinal ischaemia/infarction Heart –

LVH, LVF, MI, AF

Kidney – nephrosclerosis, renal failure

CARDIOVASCULAR EXAMINATION

CARDIAC MURMURS *MANOEVURES AND DYNAMIC AUSCULTATION*

Pansystolic
Mitral regurgitation, VSD
Listen apex, radiates axillae, valsalva manoeuvre, LV S3

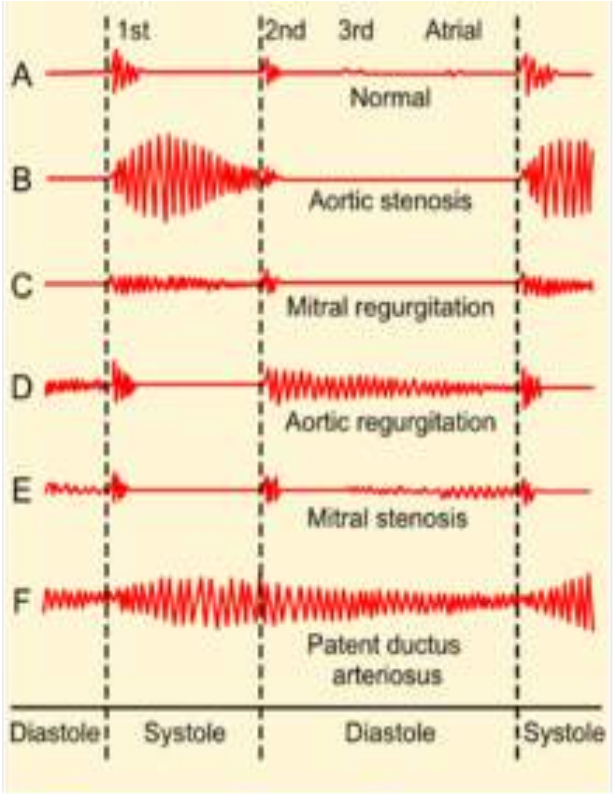

Phonocardiograms from normal and abnormal heart sounds

Ejection systolic (crescendo decrescendo)
Aortic stenosis, ASD
Listen aortic area, radiates carotids, expiration, sitting up

Late systolic
Mitral prolapse

Early diastolic (decrescendo)
Aortic regurgitation
Listen aortic area, radiates L sternal edge, expiration, sitting forward

Mid Diastolic
Mitral stenosis
Listen bell, left lateral, exercise

RESPIRATORY EXAMINATION

PNEUMONIA

INTRODUCE EXPLAIN CONSENT WASH HANDS

Position: sitting on the edge of the bed with shirt off

General Inspection

- Patient orientated to person time place
- Dyspnoea, cough
- Respiratory distress: use of accessory muscles, nasal flaring, intercostal recessions
- Signs of fever (sweating, shivering)
- Signs of pain

Vital Signs

- HR – hypertension
- Respiratory rate – tachycardia
- BP - normal
- Temperature – febrile

Hands

- Cool, sweaty palms
- CRT, peripheral cyanosis
- Nicotine staining
- CO_2 retention - flap

Face

- Mouth: peripheral cyanosis, central cyanosis, evidence URTI (erythema pharynx, tonsilar enlargement)
- Trachea: tracheal tug, tracheal deviation
- Cervical lymphadenopathy

Chest/Back

- Inspection: obvious chest wall deformity, scars, breathing (muscles, intercostals recession), chest symmetrical on breathing
- Palpation: ↑ vocal fremitus affected side, ↓ expansion on affected side
- Percussion: dull over affected area
- Auscultation: ↑ vocal resonance, bronchial breathing, mid-late inspiratory crackles, ?pleural rub

Causes of Pneumonia

Lobar: pneumococcal (90% cases), *H. influenza*, staphylococcal

Bronchopneumonia (lobular):
Bacteria – *H. influenza* and *S. pneumoniae*
Viruses – influenza, adenovirus, measles, CMV

COMMUNITY ACQUIRED PNEUMONIA

Streptococcus pneumoniae, Mycoplasma pneumoniae,Chlamydia pneumoniae also – *H. influenza*

RESPIRATORY EXAMINATION

COPD

INTRODUCE	EXPLAIN	CONSENT	WASH HANDS

Position: sitting on the edge of the bed with shirt off

General Inspection

- Body habitus – cachectic
- Fatigued, dyspnoea, cough, plethora, cyanosis
- Plethora, cyanosis
- Respiratory distress: use of accessory muscles, nasal flaring, intercostal recessions
- Barrel chest, pursed lips breathing (emphysema), tripod position

Vital Signs

- HR - normal
- Respiratory rate – tachypnea
- BP - normal
- Temperature - febrile (in an infective exacerbation)

Complications

- Cancer (clubbing, Pemberton's)
- Liver disease (cirrhosis)
- RVF – cor pulmonale (peripheral oedema, ↑JVP, hepatomegaly)

Hands

- Cool, dry palms
- CRT, peripheral cyanosis
- Nicotine staining
- CO_2 retention flap

Face

- Mouth: peripheral cyanosis, central cyanosis, evidence URTI (erythema pharynx, tonsilar enlargement)
- Trachea: tracheal tug, tracheal deviation
- Cervical lymphadenopathy (infective exacerbation)

Chest/Back

- Inspection: obvious chest wall deformity, scars, breathing (muscles, intercostal recession), chest symmetrical on breathing
- Palpation: ↓chest-expansion (hyperinflation), Hoover's sign (anterior – fingers move closer together on inspiration when testing chest-expansion)
- Percussion: dull over affected area
- Auscultation: ↑vocal resonance, ↓breath sounds, inspiratory crackles, expiratory wheeze (chronic bronchitis)

Legs

- Peripheral cyanosis

- ☐ expansion, hyperinflated chest
- ☐ vocal resonance and fremitus
- ☐ breath sounds

RESPIRATORY EXAMINATION

INTERSTITIAL LUNG DISEASE

INTRODUCE EXPLAIN CONSENT WASH HANDS

Position: sitting on the edge of the bed with shirt off

General Inspection

- Body habitus
- Dypsnoea, cyanosis
- Respiratory distress: use of accessory muscles, nasal flaring, intercostal recessions
- Cough

Vital Signs

- HR - normal
- Respiratory rate – tachypnea
- BP - normal
- Temperature - normal

Hands

- Cool, dry palms
- Peripheral cyanosis, clubbing
- Nicotine staining
- CRT

Upper Lobe - *SCART*

silicosis, coal pneumoconiosis, ankylosing spondylitis/aspergillosis, radiation, TB

Lower Lobe - *RASIO*

Rheumatoid arthritis, asbestosis, scleroderma, idiopathic/interstitial fibrosis and other (drugs)

Head and Neck

- Mouth: peripheral and central cyanosis
- Trachea: tracheal tug, tracheal deviation

Chest/Back

- Inspection: obvious chest wall deformity, scars, breathing (muscles, intercostal recession), chest movement on inspiration
- Palpation: slight decrease in chest expansion
- Percussion
- Auscultation: fine (Velcro-like) late or pan-inspiratory crackles over affected lobes

Legs

- Peripheral cyanosis

Look for signs of associated CT disease: rheumatoid arthritis, SLE, scleroderma, Sjögren's syndrome, polymyositis and dermatomyositis

RESPIRATORY EXAMINATION

LUNG CANCER

INTRODUCE	EXPLAIN	CONSENT	WASH HANDS

Position: sitting on the edge of the bed with shirt off

General Inspection

- Body habitus – fatigued, cachectic, wasting
- Dyspnoea, cough
- Facial plethora, pallor, cyanosis
- Respiratory distress: use of accessory muscles, nasal flaring, intercostal recessions

Vital Signs

- HR – may be increased
- Respiratory rate – tachypnea
- BP – normal
- Temperature – may be febrile

Hands

- Palms: Warm/sweaty/cool/dry; pallor of palmar creases; wasting of small muscles; finger weakness with abduction/adduction
- Nails: clubbing, tar staining, CRT, peripheral cyanosis
- Wrists: CO_2 retention tremor (asterixis), wrist tenderness (hypertrophic pulmonary osteoarthropathy)
- Pemberton's sign, axillary lymphadenopathy

Head and Neck

- Face: plethora
- Eyes: conjunctival pallor, Horner's syndrome (ptosis, miosis, anhydrosis)
- Mouth: peripheral and centra lcyanosis
- Trachea: tracheal tug, tracheal deviation
- Cervical lymph nodes

Chest/Back

- Inspection: obvious chest wall deformity, scars, breathing (muscles, intercostals recession), chest symmetrical on breathing, radiotherapy marks
- Palpation: chest-expansion, tactile fremitus, bony tenderness of ribs (metastases)
- Percussion
- Auscultation: comment on bronchial/vesicular breath sounds, adventitious sounds; vocal resonance

Abdomen - hepatomegaly

Legs - peripheral cyanosis

Neurological - Test CN III (pupils, accommodation, EOM), CN IX (recurrent laryngeal palsy) and upper limb

RESPIRATORY EXAMINATION

ASTHMA

INTRODUCE	EXPLAIN	CONSENT	WASH HANDS

Position: sitting on the edge of the bed with shirt off

General Inspection

- Body habitus
- Cyanosis, pallor
- Respiratory distress: use of accessory muscles, nasal flaring, intercostal recessions
- Full sentences, wheezing, cough

Vital Signs

- HR - tachycardia (pulsus paradoxus)
- Respiratory rate – tachypnea
- BP – hypertension
- Temperature – febrile (infective exac.)

Signs of Severe Asthma

i)	Exhaustion/fever
ii)	Inability to speak
iii)	Drowsiness (hypercapnia)
iv)	Cyanosis

Hands

- Cool, dry palms
- Peripheral cyanosis
- CRT
- CO_2 retention flap

Head and Neck

- Mouth: peripheral and central cyanosis
- Trachea: tracheal tug, tracheal deviation
- Cervical lymphnodes

Chest/Back

- Inspection: obvious chest wall deformity, scars, breathing (muscles, intercostals recession), chest shape/symmetry, chest wall movement decreases
- Palpation: ↑ expansion, ↑ tactile fremitus
- Percussion: hyper-resonance
- Auscultation: bilateral air entry, ↓ breath sounds, wheeze, crackles, ↑ vocal resonance, ↑ expiratory time

Legs – peripheral cyanosis

RESPIRATORY EXAMINATION

PNEUMOTHORAX

INTRODUCE	EXPLAIN	CONSENT	WASH HANDS

Position: sitting on the edge of the bed with shirt off

General Inspection

- Alert/conscious ?altered mental state
- Body habitus, dyspnoea
- Respiratory distress: use of accessory muscles, nasal flaring, intercostal recessions
- Anxious (sweaty), pain
- Obvious cyanosis

Vital Signs

- HR - tachycardia (may have pulsus paradoxus)
- Respiratory rate – tachypnea
- BP – hypertension
- Temperature - normal

Hands

- Warm/sweaty/cool/dry
- Peripheral cyanosis
- CRT

Head and Neck

- Mouth: peripheral and central cyanosis
- JVP
- Trachea: tracheal tug, tracheal deviation

Causes of Pneumothorax Spontaneous

Subpleural bullae rupture (tall, healthy, young males), emphysema with rupture of bullae (middle-aged/elderly pts), asthma, lung abscess, bronchial carcinoma, iatrogenic (central venous catheter)

Traumatic

Rib fracture, penetrating chest wall injury, during pleural/pericardial aspiration

Chest/Back

- Inspection: obvious chest wall deformity, scars, breathing (muscles, intercostals recession), chest asymmetrical
- Palpation: chest-expansion reduced on affected side, ↓ tactile fremitus
- Percussion: hyper-resonant
- Auscultation: distant or absent breath sounds; adventitious lung sounds (crackles, wheeze – ipsilateral)

CVS - apex beat displacement

Legs – peripheral cyanosis

HAEMATOLOGICAL EXAMINATION

ANAEMIA

INTRODUCE EXPLAIN CONSENT WASH HANDS

Position: patient sitting on a chair or side of bed

General Inspection

- Weight loss, frontal bossing (haemolytic anaemia)
- Racial origin (thalassaemia)
- Pallor, plethora (polycythaemia), bruising (thrombocytopenia), jaundice (haemolysis)
- Fatigue
- Obvious chronic disease

Vital Signs

- HR – tachycardia
- RR – tachypnea
- BP – wide pulse pressure
- Temperature – febrile (malaria – fever)

Hands

- Palmar crease pallor
- CRT
- Nails: koilonychia, nail bed pallor
- Purpura (haemorrhage)

Face

- Eyes: conjunctival pallor, scleral icterus, scleral injection
- Mouth: hereditary telangiectasiae (GI bleed), angular stomatitis (iron deficiency anaemia), atrophic glossitis (IDA), mucosal pallor, mucosal haemorrhages

CVS

- Signs of CCF (pulmonary oedema – bibasal creps; peripheral oedema)
- Systolic flow murmur

Abdomen (patient lying down, one pillow beneath head)

- Hepatosplenomegaly
- DRE, genital examination

Legs

- Peripheral neuropathy (vit B_{12} deficiency)
- Ulceration (sickle cell anaemia)
- Bruising

HAEMATOLOGICAL EXAMINATION

LYMPHOMA/LEUKAEMIA

INTRODUCE	EXPLAIN	CONSENT	WASH HANDS

Position: sitting in a chair or on edge of bed

General Inspection

- Generally unwell
- Weight loss and muscle wasting
- Pallor (anaemia), petechiae (thrombocytopaenia)
- Weight loss & muscle wasting
- Infection, malaise

Vital Signs

- Pulse – tachycardia
- BP - hypertension
- RR – tachypnoea
- Fever (infection 2^0 to neutropaenia)

Hands

- Palmar crease pallor
- CRT
- Digital infarction (cryoglobulinaemia – multiple myeloma)

Arms

- Epitrochlear lymphadenopathy (ALL)
- Axillary lymphadenopathy (ALL)

Face

- Conjunctival pallor
- Tonsillar enlargement (ALL)
- Gum hypertrophy and bleeding (AML)
- Cervical lymphadenopathy (ALL)

Abdomen

- Splenomegaly (ALL)
- Hepatomegaly
- Para-aortic lymphadenopathy (ALL)
- Inguinal lymphadenopathy (ALL)

Respiratory: pleural effusions, infection

GIT EXAMINATION

ALCOHOLIC LIVER DISEASE

INTRODUCE EXPLAIN CONSENT WASH HANDS

Position: patient lying flat on bed, one pillow beneath head

General Inspection

- Body habitus (cachexia)
- Alert/conscious, orientated to person, place and time (hepatic encephalopathy)
- Distressed/in pain (peritonitis)
- Obvious jaundice, pallor, skin pigmentation (haemochromatosis)

Vital Signs

- HR – tachycardia
- BP – hypotension, postural variation
- RR – tachypnea, shallow breathing
- O_2 sats, temperature, GCS

Hands

- Warm/cool, dry/sweaty
- Palms: pallor palmar creases, palmar erythema, Dupuytren's contracture
- Nails: leuchonychia and Muerhcke's lines (hypoalbuminaemia), clubbing
- CRT
- Tremor (asterexis) and hepatic flap

Arms

- Bruising, petechiae
- Scratch marks
- Spider naevi
- Proximal myopathy

Face

- Eyes: scleral jaundice, conjunctival pallor, xanthelasma
- Parotid gland enlargement
- Mouth: angular stomatitis, alcohol on breath, fetor hepaticus, leukoplakia, atrophic glossitis, hydration

Chest

- Gynaecomastia and spider naevi

Abdomen

- Inspection: abdominal distension, prominent veins (caput medusa), abnormal skin pigmentation
- Palpation: light and deep (tenderness - ?rebound, guarding, rigidity); hepatomegaly, splenomegaly
- Percussion: ascites
- Auscultation: venous hum, liver bruit
- Testicular atrophy

Legs

- Oedema, bruising
- Muscle wasting

Additional Examinations

- Cardiovascular
- Respiratory
- Neurological

GIT EXAMINATION

INFLAMMATORY BOWEL DISEASE

INTRODUCE	EXPLAIN	CONSENT	WASH HANDS

Position: patient lying flat on bed, one pillow beneath head

General Inspection

- Body habitus (cachexia)
- Distressed/in pain/malaise
- Pallor, jaundice ('signs of primary sclerosing cholangitis')

Vital Signs

- HR – tachycardia
- BP – hypotension
- RR – tachypnea
- O_2 sats, temperature

Hands

- Warm/cool, dry/sweaty
- Pallor palmar creases, clubbing (malabsorption)
- Arthritis
- CRT

Face

- Conjunctival pallor, scleral jaundice
- Conjunctivitis, iritis, episcleritis
- Mouth: ulcers, angular stomatitis, atrophic glossitis

Abdomen

- Inspection: abdominal distention, visible masses
- Palpation: light and deep (tenderness - ?rebound, guarding, rigidity)
- Percussion: ascites
- Auscultation: bowel sounds
- Rectal examination

Legs

- Skin lesions
  - Erythema nodosum
  - Pyoderma gangrenosum

GIT EXAMINATION

ACUTE ABDOMEN

INTRODUCE EXPLAIN CONSENT WASH HANDS

Position: patient lying flat on bed, one pillow beneath head

General Inspection
- Distressed/in pain
- Pallor, diaphoresis
- Lack of movement with respiration

Vital Signs
- HR – tachycardia, reduced volume
- BP – hypotension, postural hypotension
- RR – tachypnea, shallow breathing
- O_2 sats, temperature, GCS

Hands
- Warm/cool, dry/sweaty
- CRT

Mouth hydration

Abdomen
- Inspection: ↓ movement with respiration, splinting of abdominal muscles, abdo. Distension, visible masses, prominent veins, pulsations, abdo. scarring
- Palpation: light & deep (tenderness - ?rebound, guarding, rigidity); hepatomegaly/atrophy, splenomegaly, aorta
- Auscultation: bowel sounds
- Rectal, genital and hernia examinations

Cholecystitis
- Murphy's sign = on taking a deep breath patient catches his or her breath when inflamed gallbladder presses on examiner's hand lying at costal margin

Appendicitis
- McBurney's point = point 1/3rd distance from anterior superior iliac spine to umbilicus on right
- Rovsing's sign = press fingers in left lower quadrant and quickly withdraw fingers, positive if pain in right iliac fossa during left sided pressure
- Psoas sign = place hand above patient's right knee and ask patient to raise thigh against hand increased pain during manoeuvre
- Obturator sign = flex right thigh at hip and knee bent then internally rotate leg at hip ! right
- hypogastric pain

Additional
- Respiratory: consolidation, pleural rub, pleural effusion
- Cardiovascular: atrial fibrillation (embolism mesenteric artery), signs MI

GIT EXAMINATION

COLON CANCER

INTRODUCE	EXPLAIN	CONSENT	WASH HANDS

Position: patient lying flat on bed, one pillow beneath head

General Inspection
- Body habitus (cachexia)
- Distressed/in pain
- Pallor, jaundice (liver mets)

Vital Signs
- HR – tachycardia
- BP – hypotension
- RR – tachypnea
- O_2 sats, temperature, GCS

Hands
- Warm/cool, dry/sweaty
- Pallor palmar creases
- CRT
- Clubbing

Face
- Eyes
  - Scleral jaundice, conjunctival pallor
- Mouth
  - Peripheral and central cyanosis
  - Angular stomatitis
  - Brown black lesions (Peutz-Jeghers syndrome – polyps GIT)
  - Atrophic glossitis
  - Hydration

Neck supraclavicular lymph nodes - Virchows node (gastric malignancy)

Abdomen
- Inspection: abdominal distention, visible masses, skin lesions, scars, prominent veins, visible peristalsis, pulsations
- Palpation: light and deep (tenderness - rebound, guarding, rigidity); hepatomegaly (liver mets), paraortic lymph nodes, inguinal lymph nodes
- Percussion: ascites
- Auscultation: bowel sounds

Rectal and genital examination

ENDOCRINE EXAMINATION

DIABETES

INTRODUCE	EXPLAIN	CONSENT	WASH HANDS

Position: patient sitting on a chair or side of bed

General Inspection

- Body habitus – central adiposity, evidence weight loss
- Are they alert/conscious, oriented
- Skin pigmentation (haemochromatosis)
- Endocrine facies (Cushing's, acromegaly)
- Hydration

Vital Signs

- BP – hypertension, postural hypotension
- HR – tachycardia
- RR - tachypnoea
- Temperature – febrile (infection)
- BMI

Legs

- Inspection:
  - Structural deformity: bunions, hallux valgus (big toe bent medially), pes cavus (high arch/ claw foot), claw toes, loss transverse arch
  - Vascular: pedal oedema; thin atrophic and shiny skin, loss of hair; thickening of nails; venous stasis changes and skin discolouration
  - Superficial skin infection (LOOK BETWEEN TOES): fungal nail infections, boils, cellulitis
  - Neuropathic: dry skin, calluses (circular hyperkeratoticc areas) and ulcers, neuropathic (Charcot's) joints, wasting of the quadriceps
  - Specific skin manifestations: necrobiosis lipoidica diabeticorum (fx of lipid necrosis), diabetic dermopathy (pigmented scars over shin), injection sites fat atrophy or hypertrophy
- Palpation:
  - Temperature
  - Peripheral pulses (femoral, popliteal, posterior tibialis, dorsalis pedis)
  - CRT
- Sensory:
  - Light touch sensation (10g monofilament) – eyes closed and asked to say yes or no if they feel or don't
  - Vibration (128 Hz tuning fork) – ask if vibration feels the same on the MTP as it is on the sternum
  - Pain – demonstrate on the sternum, ask if sharp or dull sensation in LOWER DERMATOME PATTERN
  - Proprioception

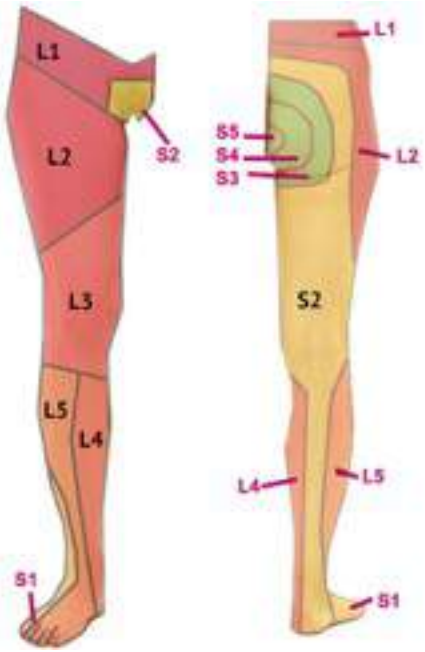

- Motor:
  - Movement – power and range
    - Hip
    - Knee
    - Ankle
  - Reflexes
    - Knee
    - Ankle
    - Plantar (flexion of the toes)

Hands/Arms

- Skin lesions
- Injection sites

Face

- Eyes: xanthelasma, visual acuity, EOM (CN palsies), fundoscopy (diabetic and hypertensive retinopathy)
- Mouth: infection (candida), fetor (ketotic), hydration

Neck

- Acanthosis nigricans – axillae, inguinal folds and neck (hyperinsulinaemia)

Chest

- CVS: carotid bruits, signs of HTN
- RS: infection

Abdomen

- Injection sites
- Hepatomegaly (fatty liver, haemochromatosis)
- Tenderness

Diabetic Retinopathy

- Microaneurysms
- Haemorrhages – dot and blot
- Exudates
- Cotton wool spots
- Intra-retinal microvascular abnormalities – dilated, tortuous capillaries
- Venous changes – 'beading'
- Neovascularissation

Additional Examinations

- Retinal (fundoscopy)
- Renal/urological

Investigations

- HbA1c, U+E . lipids, LFT, FBC
- BUN, albumin, creatinine

Diagnostic Criteria for Diabetes Mellitus

Symptoms + unexplained wt loss AND

Fasting plasma venous BSL ≥7mmol/L OR 2-

hour postprandial BSL ≥11.1mmol/L

ENDOCRINE EXAMINATION

HYPERTHYROIDISM

INTRODUCE	EXPLAIN	CONSENT	WASH HANDS

Position: patient sitting on a chair or side of bed

General Inspection
- Body habitus – weight loss
- Anxious, sweating
- Thyroid facies

Vital Signs
- HR – tachycardia, atrial fibrillation, collapsing (high CO)
- BP – hypertension
- RR – tachypnoea
- Temperature

Hands/Arms
- Warm sweaty palms
- Palmar erythema
- Onycholysis
- Thyroid acropachy (clubbing, swollen fingers, periosteal bone formation – Grave's disease)
- Fine tremor (sympathetic overactivity)
- Proximal myopathy
- Pemberton's sign
- Hyperreflexia biceps tendon

Face
- Exopthalmos, lid retraction, ptosis
- Lid lag
- Visual acuity, EOM, visual fields, fundoscopy

Thyroid/Neck
- Inspection: swelling, scar, erythema, prominent veins, sip water
- Posterior palpation: swelling, sip water, thrills, stridor, cervical lymphadenopathy
- Anterior palpation: swelling, sip water, tracheal displacement, carotid pulse
- Percussion: upper manubrium
- Auscultation: bruits thyroid

Chest
- Gynaecomastia
- CVS: systolic flow murmur, signs of CCF (dull lung bases, bibasal creps)

Legs
- Proximal myopathy
- Pretibial myxedema
- Hyperreflexia

ENDOCRINE EXAMINATION

HYPOTHYROIDISM

INTRODUCE	EXPLAIN	CONSENT	WASH HANDS

Position: patient sitting on a chair or side of bed

General Inspection
- Body habitus – weight gain
- Myxedema madness, hypothyroid speech (deep pitch, slow, nasal), mental and physical sluggishness
- Myxoedema facies
- Dry, thickened skin

Vital Signs
- HR – bradycardia, small volume
- BP – hypertension
- RR – tachypnoea
- Temperature – hypothermia
- BMI

Hands/Arms
- Cold dry palms
- Palmar crease pallor (anaemia of chronic disease)
- Hypercarotinemia (↓ hepatic metabolism carotene)
- Peripheral cyanosis (↓ CO)
- CRT (↓)
- Proximal myopathy
- Pembertons sign, hung up biceps reflex

Face
- Hair: alopecia, dry thin hair, loss outer 1/3 eyebrows
- Skin: hypercarotinaemia, vitiligo, thickening skin
- Eyes: periorbital oedema, xanthelasma, conjunctival pallor
- Swelling tongue

Thyroid/Neck
- Inspection: swelling, scar, prominent veins, sip water
- Posterior palpation: swelling, sip water, cervical lymphadenopathy
- Anterior palpation: swelling, sip water, tracheal displacement, carotid pulse
- Percussion: upper manubrium

Chest
- Pleural and pericardial effusions

Legs
- Proximal myopathy
- Non-pitting oedema, peripheral neuropathy
- Hung-up Achilles reflex

Neurological Examination

- Sensory loss carpal tunnel
- Nerve deafness

ENDOCRINE EXAMINATION

CUSHING'S SYNDROME

INTRODUCE EXPLAIN CONSENT WASH HANDS

Position: patient sitting on a chair or side of bed

General Inspection

- Body habitus – thin limbs, truncal adiposity, buffalo hump (fat deposition interscapular area), moon like facies
- Are they alert/conscious? (steroid psychosis)
- Bruising (protein catabolism) and hyperpigmentation of extensor surfaces (↑ACTH = ↑melanin)

Vital Signs

- HR – tachycardia, atrial fibrillation
- HR – hypertension (aldosterone)
- RR – tachypnoea
- BSL – hyperglycaemia
- Temperature, O_2 sats

Hands/Arms

- Warm/cool, dry/sweaty
- CRT, thinning of skin folds
- Proximal myopathy

Face

- Plethora; Moon shape face (fat deposition)
- Acne and hirsuitism (↑ adrenal androgen)
- Telangiectasia
- Visual fields (pituitary tumor = bi-temporal hemianopia)
- Fundoscopy (optic atrophy, papilloedema, hypertensive and diabetic changes)

Neck - supraclavicular fat pads

Chest

- Gynaecomastia
- Bony tenderness (compression fracture)

Abdomen

- Inspection: purple striae (weakening and disruption collagen fibres)
- Palpation: hepatomegaly (fat deposition, adrenal ca deposition), adrenal masses
- Percussion: ascites

Legs

- Wasting quadriceps muscles
- Proximal myopathy
- Oedema, bruising, poor wound healing

ENDOCRINE EXAMINATION

ACROMEGALY

INTRODUCE	EXPLAIN	CONSENT	WASH HANDS

Position: patient sitting on a chair or side of bed

General Inspection
- Body habitus: spade-like hands, proximal myopathy
- Characteristic face: frontal bossing, papilloedema

Vital Signs
- BP (↑), HR (↑), RR, Temp

Hands
- Warm and sweaty; thickened skin
- Wide spade-like shape, osteoarthritis and median nerve entrapment

Arms
- Proximal myopathy (abduct); ulnar nerve thickening
- Axillae: molluscum fibrosum, greasy skin, acanthosis nigricans

Face
- Supraorbital ridge (frontal bossing)
- Thick lips
- Eyes: bitemporal hemianopia; fundoscopy: optic atrophy and papilloedema; angioid streaks; ocular palsies
- Mouth: enlarged tongue, teeth splayed and separated, malocclusion, lower jaw square and firm

Neck
- Thyroid may be diffusely enlarged (growth hormone)
- Hoarse voice

Chest
- Coarse body hair and gynaecomastia
- CVS: arrhythmias, cardiomegaly, CCF (acromegaly = ↑ IHD, HTN and cardiomyopathy)
- Back look for kyphosis

Abdomen
- Hepatic, splenic and renal enlargement
- Testicular atrophy (hyperprolactinaemia with mixed pituitary tumours)

Lower Limbs
- Hip and knee OA
- Pseudogout
- Foot drop (common peroneal nerve entrapment)

NEUROLOGICAL EXAMINATION

UPPER LIMB

INTRODUCE	EXPLAIN	CONSENT	WASH HANDS

Position: patient sitting on a chair or side of bed

General Inspection

- Orientated to person time place
- Abnormal posture, asymmetry body
- Involuntary movements, muscle wasting, scars, skin lesions

Vital Signs

- BP, HR, RR, Temp

Motor

Inspection

- Is the patient left or right handed?
- Hands by side – look for fasciculations (LMN lesion)
- Pronator drift: ask patient to hold out both hands w arms extended and eyes closed – turn palms upwards
  - Downward drift: pyramidal lesion
  - Upward drift: cerebellar lesion
  - Any direction: loss of proprioception

Bulk

- Atrophy (best seen in hands and shoulders)
  - Atrophy + fasciculations = LMN disease

Tone

- Note resistance to passive movement by supporting patient's arm with one hand and passively moving with other the other. Move each joint through full ROM.
  - May be reduced = acute phase spinal cord injury
  - Increased = UMN or extrapyramidal lesion
  - Rigid (cogwheel) = Parkinson's disease
    - 'clasp knife like' = lesions of pyramidal tract

Strength/Power

Remember to compare from side to side

- Shoulder
  - Abduction (C5, C6) – ask patient to abduct arms with elbows flexed against resistance
  - Adduction (C6, C7) – ask patient to adduct arms with elbows flexed against resistance
- Elbows
  - Flexion (C5, C6) – ask patient to bend elbow against resistance
  - Extension (C7, C8) – ask patient to extend elbow against resistance
- Wrist
  - Flexion (C6, C7) – ask patient to make a fist (examiner must isolate the wrist) and then bend, not allowing the examiner to straighten it
  - Extension (C6, C7, C8 – radial nerve) – ask patient to make a fist then extend the wrist and not allow the examiner to bend it
- Fingers
  - Flexion (C7, C8) – ask patient to squeeze examiner's fingers (Grip strength)
  - Extension (C7, C8) – ask patient to straighten fingers against resistance
  - Finger abduction (C8, T1 – median nerve) – patient spreads fingers against resistance

- Finger adduction (C8, T1) – patient holds fingers together and doesn't let examiner separate them
- Thumb opposite (C8, T1 – median nerve) – patient makes ring with thumb and forefinger and examiner tries to open the ring

Reflexes

- Biceps (C5, C6) – with patient's arm flexed at the elbow, palm down – place thumb on bicepstendon
- Triceps (C6, C7) – with patient's arm flexed at the elbow, palm towards the body – strike triceps tendon directly
- Supinator/brachioradials (C5, C6) –patient's arm resting and partially pronated, fingers 2 inches above radial wrist

Coordination

- Rapid alternating movements: extend left forearm, elbow flexed and palm facing up – place dorsum of right hand onto left palm and then turn right hand over and then back up ! 'do this as rapidly and accurately as possible'
- Dysdiachokinesis = cerebellar dysfunction
- Finger nose test: eyes open pt is asked to touch their own nose with index finger and then examiner's forefinger at nearly full extension repeated 2/3 times. Repeat with eyes closed.
- Past-pointing and intention tremor = cerebella dysfunction
- Rebound: ask patient to lift arms rapidly from both sides and then stop

Sensory System

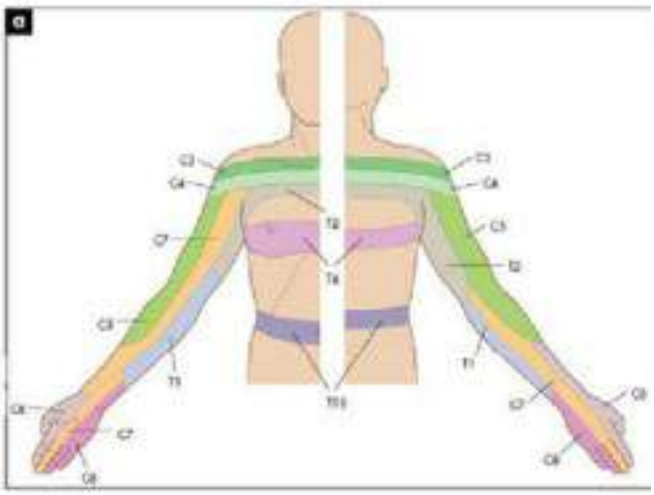

Important Dermatomes to remember:

- C3 – front of neck
- T4 – nipples
- T7 – xiphisternum
- T10 – umbilicus
- L1 – inguinal

Pain is always assessed first, and light touch last

Pain

- Check neurotip on sternum pinprick various dermatomes – start compare both sides. Aask whether it feels sharp or dull
-

Position: move DIP joint of little finger up and down

- First demonstrated with eyes open – grasp phalanx by the sides
- Repeat with eyes closed and ask patient to identify whether the DIP is pointing up or down
- Abnormality = move proximally
- Loss of position sense = posterior column disease/lesion in peripheral nerve/root

Vibration (128Hz tuning fork)

- Place on the patient's sternum
- With eyes closed – place vibrating tuning fork on DIP joint of patient's thumb ! stop the tuning fork
- and ask patient to let you know when they feel the vibration stop
- Abnormality = move to proximal bony prominences
- First sensation lost in peripheral neuropathy (diabetes)

Light Touch

- Use cotton wool – least discriminative and therefore tested last
- Ask patient to close eyes and say 'yes' when TOUCH is felt (do not stroke)

Pain/Temperature – spinothalamic

Position/vibration – posterior column

Light touch – posterior column and spinothalamic

NEUROLOGICAL EXAMINATION

UPPER LIMB

INTRODUCE EXPLAIN CONSENT WASH HANDS

'IMT-PRCS'

Position: patient sitting on a chair or side of bed

Vital Signs: BP HR, RR, TEMP

Inspection	▪ Orientated to person time and place ▪ Abnormal posture asymmetry, involuntary movements, fasciculations ▪ Muscle wasting, scars, skin lesions ▪ Handedness, fasciculations ▪ Pronator drift – ask patient to close eyes with arms supinated
Muscle Bulk	▪ Feel for muscle bulk in both arms simultaneously – note any atrophy
Tone	▪ Examiner passively moves each joint through full range of movement – note any resistance
Power	▪ Shoulders o Ask patient to form chicken wings 'don't let me push you down'; 'don't let me push them up' ▪ Elbows o Ask pt to flex elbows 'pull me towards you' 'push me away from you' ▪ Wrists o Ask pt to make a fist, isolate the wrist 'don't let me straighten your wrist'; 'don't let me bend your wrist' ▪ Fingers o Grip examiner's fingers o Abduct fingers 'don't let me close them', adduct fingers 'don't let me open them' o Form a ring with thumb and forefinger 'don't let me open the ring'
Reflexes	▪ Biceps ▪ Triceps ▪ Supinator/brachioradialis
Coordination	▪ Rapid alternating movements – dorsum of left hand on palmar surface of right hand – turn left hand over and back up 'repeat as fast and accurately as possible' ▪ Finger nose test – eyes open and eyes closed ▪ Rebound test – ask patient to lift arms rapidly from both sides and then stop
Sensation	▪ Pain: all dermatomes ▪ Position: move small finger DIP with pts eyes closed ▪ Vibration: 128Hz on thumb DIP ▪ Light touch: all dermatomes

NEUROLOGICAL EXAMINATION

LOWER LIMB

INTRODUCE	EXPLAIN	CONSENT	WASH HANDS

Position: patient either lying down or sitting on edge of bed with legs and thighs completely exposed

General Inspection

- Orientated to person time place
- Abnormal posture, asymmetry body
- Involuntary movements, fasciculations
- Muscle wasting, scars, skin lesions

Vital Signs

- BP, HR, RR, Temp

Gait

- Ask patient to walk away from you, turn quickly and walk back
- Tandem walking 'heel to toe' (cerebellear lesion)
- Toe/heel walking
  - First asked to wall on toes (S1 lesion)
  - Walk on heels (L4/L5 lesion)
- Rombergs test: patient stands with feet together and eyes open – asked to close eyes for 20-30s without support
  - +ve test – patient can stand with eyes open but not with eyes closed (loss of proprioception)

Motor System

Bulk

- Atrophy (best seen in quadriceps and calves)
  - Atrophy + fasciculations = LMN disease

Tone

- Note resistance to passive movement at knees and ankles – test all ranges of movement
- Ankle clonus: sharply dorsiflex the foot with knee bent and thigh externally rotates
  - Present = recurrent ankle plantar flexion movement

Strength/Power

Remember to compare from side to side

- Hip
  - Flexion (L2, L3, L4) – keeping legs straight, ask patient to raise it from the bed against resistance
  - Extension (L5, S1, S2) – ask patient to keep leg down and not let you pull it up
  - Adduction (L2, L3, L4) – ask patient to bring legs together
  - Abduction (L2, L3, L4) – ask patient to open their legs
- Knee
  - Extension (L3, L4) – with knee slightly bent, ask patient to straighten knee against resistance
  - Flexion (L5, S1) – ask patient to bend knee against resistance
- Foot
  - Dorsiflexion (L4, L5)
  - Plantar flexion (S1)

patient has already had these tested during gait

Reflexes

- Knee jerk (L2, L3, L4) – patient seated with legs flexed over the edge of bed, strike patellartendon and watch for contraction of quadriceps
- Ankle jerk (S1) – with knee bent and thight externall rotated on bed, dorsiflex the ankle and strike Achilles tendon with knee hammer – watch for plantar flexion
- Plantar reflex (L5, S1, S2) – with patient supine or seated, stroke lateral aspect of the sole of foot from the heel curving over plantar surface of ball of foot using a blunt object. Normal response is flexion of the big foot.
    - Extension and fanning of toes = Babinski's response (UMN lesion – normal in infants)

Coordination

- Heel to shin test: with patient lying on bed, ask them to place heel of one foot on opposite knee and slide heel down shin to big toe at a moderate pace and as accurately as possible
    - Clumsy/heel moving side to side (overshooting) = cerebellar dysfunction
- Toe-finger test: ask pt to lift foot and touch examiner's finger with big toe
- Foot-tapping test: ask pt to tap foot alternately on examiner's hand as fast and accurately aspossible

Sensory System

Pain/Temperature – spinothalamic

Position/vibration – posterior column

Light touch – posterior column and spinothalamic

Important Dermatomes to remember:

- C3 – front of neck
- T4 – nipples
- T7 – xiphisternum
- T10 – umbilicus
- L1 – inguinal

Pain is always assessed first, and light touch last

Pain

- Check neurotip on sternum
- Pinprick various dermatomes – start proximally and compare

Position: move DIP joint of big toe up and down

- First demonstrated with eyes open – grasp toe by the sides rather than the pulp
- Repeat with eyes closed and ask patient to identify whether the DIP is pointing up or down
- Abnormality = move proximally

Vibration (128Hz tuning fork)

- Place on the patient's sternum
- With eyes closed – place vibrating tuning fork on DIP joint of patient's big toe stop the tuning fork and ask patient to let you know when they feel the vibration stop
- Abnormality = move to proximal bony prominences
- First sensation lost in peripheral neuropathy (diabetes)

Light Touch

- Use cotton wool – least discriminative and therefore tested last
- Ask patient to close eyes and say 'yes' when TOUCH is felt (do not stroke)

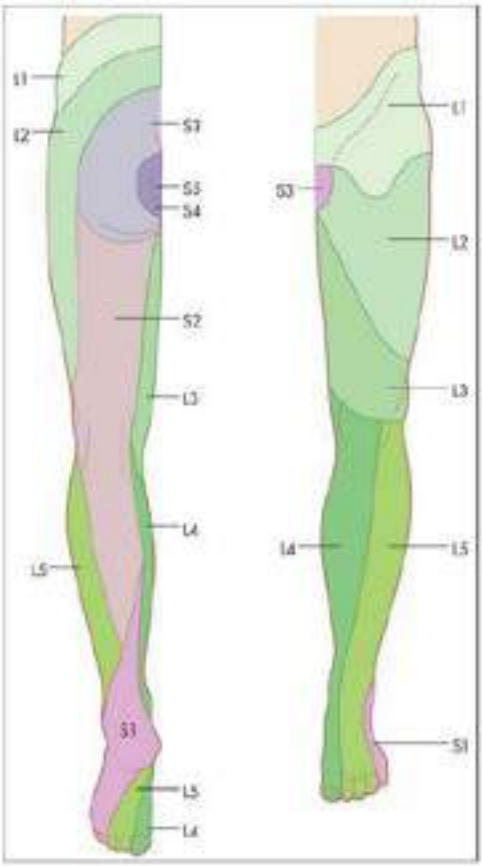

NEUROLOGICAL EXAMINATION

LOWER LIMB SUMMARY

INTRODUCE EXPLAIN CONSENT WASH HANDS

Position: patient sitting on a chair or side of bed
Vital Signs: BP HR, RR, TEMP

'I(G)MT-PRCS'

Inspection	▪ Abnormal posture, asymmetry, involuntary movements, fasciculations ▪ Muscle wasting, scars, skin lesions ▪ Orientated to person time and place
Gait	▪ Ask pt to walk away from you, turn quickly and walk back ▪ Walk heel to toe, walk on toes, walk on heels ▪ Rombergs test: pt stands w feet together and closes eyes for 20-30s without support
Muscle Bulk	▪ Feel for muscle bulk in both legs simultaneously – note any atrophy esp quads and calves
Tone	▪ Examiner passively moves each joint through full range of movement – note any resistance ▪ Ankle clonus: sharply dorsiflex foot w knee bent and thigh externally rotated = recurrent ankle plantar flexion movement
Power	▪ Hip o ask pt to keep legs straight and up off the bed 'don't let me push them down'; 'keep your legs down and don't let me pull them up' o 'bring your legs together'; 'place your legs apart' ▪ Knee o ask pt to bend knee slightly – 'push me away' 'pull me towards you' ▪ Foot o Dorsiflexion and plantar flexion tested in gait
Reflexes	▪ Knee Jerk ▪ Ankle Jerk ▪ Plantar reflex
Coordination	▪ Heel to shin test ▪ Toe-finger test ▪ Foot-tapping test
Sensation	▪ Pain: all dermatomes ▪ Position: move big toe DIP with pts eyes closed ▪ Vibration: 128Hz on big toe DIP ▪ Light touch: all dermatomes

NEUROLOGICAL EXAMINATION

CRANIAL NERVES

INTRODUCE	EXPLAIN	CONSENT	WASH HANDS

Position: patient sitting on a chair or side of bed

General Inspection

- Wasting of facial muscles, facial symmetry
- Involuntary movements
- Ptosis (drooping of eyelid), inability to close eye
- Orientated to person, place and time

Vital Signs

- BP, HR, RR, Temp

Cranial Nerves

CNI – Olfactory

- Question – any loss smell (anosmia)
- External appearance of nose

CNII – Optic

- Visual acuity (with glasses, each eye separately)
- Visual fields (confrontation with red tip)
- Fundus (cornea, iris, lens)

CNIII, IV, VI (Occulomtor, Trochlear, Abducens)

- Pupil: size, shape, quality, regularity
  - Light reflex – direct, consensual, afferent pupillary defect
- Ptosis, ectropian
- Accommodation (look into distance then focus on tip finger close with constriction pupils)
- Eye movements: 'H pattern' for diplopia; move eyes right, left, up and down (convergence, strabismus, nystagmus)

CNV – Trigeminal

- Motor division
  - Temporalis muscle – inspect for wasting: hollowing of temporalis fossa
  - Masseter muscle – clench teeth and palpate muscle above mandible for loss bulk and strength
  - Pterygoid muscle – open mouth and hold open to opposition
  - Jaw jerk
- Sensory division
  - Test first on sternum for each, then over ophthalmic (forehead), maxillary (cheek), mandibular (jaw)
  - Sharp touch (neurotip) over 3 divisions – sharp or dull (dull = loss pain sensation)
  - Light touch (cotton wool) over 3 divisions with eyes closed – feel or not
  - Corneal reflex – touch cornea with wisp cotton – ask patient if felt touch, eyes should blink

CNVII – Facial

- Facial asymmetry (unilateral drooping corner mouth, smoothing of wrinkles)
- Muscle power:
  - Look up and wrinkle forehead (test muscle strength)

- Frown (smoothing of wrinkles on one side)
- Shut eyes tight and try to force open (muscle strength, Bell's phenomenon)
- Smile (loss of nasolabial folds on affected side, symmetry)
- Puff cheeks and push against (power, symmetry)

CNVIII - Vestibulocochlear

- Examine external ear – pinna, pinna tug test
- Otoscopy – external auditory meatus, tympanic membrane
- Hearing – whisper test, Rinne, Webers (256 Hz)
- Rombergs

CNIX, X – Glossopharyngeal, Vagus

- Open mouth and say ah (symmetrical rise posterior edge soft palate, deviation uvula – drawn to N side)
- Speak and cough (hoarseness, bovine cough)
- History of swallowing difficulties

CNXI – Accessory

- Shrug shoulders – muscle bulk trapezius, push shoulders down
- Turn head to left and then right against resistance (right sternocleidomastoid turns head to left), feel muscle bulk

CNXII – Hypoglossal

- Inspect tongue at rest on floor mouth – wasting, fasciculations (fine, irregular, non-rhythmical muscle fibre contractions); articulation of speech
- Poke out tongue – deviation to side of lesion (unilateral lower motor neurone lesion)
- Lesions:
  - Lower motor neurone lesion = weakness, wasting and fasciculations; dysarthria and deviation towards lesion (uni)
  - Upper motor neurone lesion = small, immobile tongue (bilateral)

Meningeal Signs

1. **Neck stiffness:** pt supine, flex the neck passively (chin is brought to the chest) – if there is resistance = meningeal irritation

2. **Brudzinski's sign**: pt supine and examiner lifts head off the bed into chin-to-chest position – if there is flexion of the hips and knees (pain) = meningeal irritation

3. **Kernig's sign:** pt supine and examiner passively flexes patient's knee and hip to 90° and then examiner tries to passively straighten the leg – pain or ↑ resistance bilaterally = meningeal irritation

NEUROLOGICAL EXAMINATION

CEREBELLAR DISEASE

INDICATIONS: *clumsiness, problems w coordination of movement*

INTRODUCE	EXPLAIN	CONSENT	WASH HANDS

Position: patient sitting on a chair or side of bed

General Inspection

- Involuntary movements
- Muscle wasting

Vital Signs

- HR – tachycardia
- BP – hypertension
- RR – tachypnoea
- O_2 sats
- Temperature - febrile

Gait

- Normal walking (stagger towards affected side in unilateral cerebellar lesion)
- Heel-to-toe walking (difficulty)
- Romberg's test (difficulty)

Face

- Repeat British Constitution' or 'West Register Street' (ataxic dysarthria and staccato speech – jerky, explosive and loud with irregular separation syllables)
- Nystagmus (towards side lesion)

Coordination

- Hands
  - Finger nose test (intention tremor and past pointing on side lesion)
  - Rapidly alternating movements (dysdiadochokinesis)
  - Rebound (hypotonia)
  - Pronator drift (upward drift – hypotonia)
- Legs
  - Heel shin test (decreased accuracy)
  - Toe finger test (intention tremor and past pointing on side lesion)
  - Foot tapping

Body

- Truncal ataxia - fold arms and sit up (loss coordinated movement)
- Pendular tendon reflex knee (hypotonia)

NEUROLOGICAL EXAMINATION

PARKINSON'S DISEASE

INTRODUCE	EXPLAIN	CONSENT	WASH HANDS

Position: patient sitting on a chair or side of bed

General Inspection

- Mask-like facies
- Muscle wasting
- Involuntary movements (spontaneous movements, resting tremor – pill rolling)
- Orientated to person, place and time

Vital Signs

- HR, RR
- BP – orthostatic hypotension
- O_2 sats and temperature

Gait

- Normal walking (shuffling gait; difficulty initiating, hurrying, difficulty stopping; lack normal arm swing)
- Heel-to-toe walking (difficulty)

Hands

- Finger tapping, finger twiddling (bradykinesia, clumsy)
- Resting tremor (serial 7s, rapid opposition contralateral thumb and fingers facilitate tremor)
- Tone wrists (cogwheel/leadpipe rigidity)
- Writing (micrographia)
- Palmomental reflex

Face

- Tremor head (titubation)
- Absence blinking
- Dribbling saliva
- Speech (monotonous, soft and faint, lack intonation, papilalion)
- Weakness upward gaze
- Greasiness/sweating brow
- Glabellar reflex

Neurological Examination

- Upper and lower body tone, power, reflexes, sensation

MUSCULOSKETAL EXAMINATION

RHEUMATOID ARTHRITIS

INTRODUCE	EXPLAIN	CONSENT	WASH HANDS

Position: patient sitting on a chair or side of bed

General Inspection
- Cushingoid appearance (steroids)
- Signs of weight loss (active disease)

Vital Signs
- BP, HR, RR, Temp

Hands
- Symmetrical small joint synovitis (DIP spared)
- Ulnar deviation, volar subluxation of MCP joints, Z deformity of the thumb
- Swan neck and boutonnière deformity of fingers
- Fingernails and periungual areas: splinter-like vasculitis changes
- Wasting of small muscles of hands, palmar erythema, palmar tendon creptius (extend and flex fingers)
- Ulnar nerve palsy and median nerve palsy

Arms
- Wrist: synovial thickening and Phalen's sign (carpal tunnel)
- Elbows: rheumatoid nodules (seropositive disease) and flexion contractures
- Shoulders: tenderness and limited movement, palpate axillary nodes

Face
- Eyes: dry eyes (Sjögren's), scleritis, episcleritis, scleromalacia perforans, conjunctival pallor, cataracts
- Fundi: hyperviscosity
- Parotid gland enlargement (Sjögren's)
- Mouth: dryness and dental caries (Sjögren's) and ulcers (Methotrexate), temporomandibular joint crepitus
- Neck: cervical tenderness, muscle spasm and ↓ rotation; cervical lymphadenopathy

Chest
- RS: pleural effusion, pulmonary fibrosis
  - Caplan's syndrome = rheumatoid lung nodules + pneumoconioses
- CVS: pericardial rub, murmurs (aortic – due to nodular heart involvement)

Abdomen
- Splenomegaly (Felty's syndrome)
- Hepatomegaly
- Inguinal lymph nodes

Lower Limbs

- Hips: limitation of joint movement
- Knees: commonly affected – quadriceps wasting, synovial effusions and flexion contractures; valgus deformity and ligamentous instability; Baker's cyst
- Ulceration (Felty's syndrome)
- Peripheral neuropathy (mononeuritis multiplex or spinal cord compression due to subluxation of odontoid process stocking distribution)
- Feet: foot drop (peroneal nerve entrapment), limited ankle movement (swelling and subluxation at MTP)
    - Lateral deviation and clawing of toes
- Achilles tendon for nodules (seropositive disease)

MUSCULOSKELETAL EXAMINATION

FOCUSSED SHOULDER

INTRODUCE	EXPLAIN	CONSENT	WASH HANDS

Position: patient sitting in a chair with their shirt off

'If you experience any pain, discomfort, if you feel uncertain/unsteady or need me to repeat anything let me know'

Vital Signs

- BP
- ↑ HR and RR (pain, infection)
- ↑Temp (infection)

General Inspection

- Symmetry, balance
- Scars, swelling, bruising, erythema, deformity

Palpation

- Sternoclavicular joint, clavicle, acromioclavicular joint
- Coracoid, long head of biceps
- Subscapularis, supraspinatus, infraspinatus and teres minor
- Lateral border scapula, medial border scapula and rhomboids, cervical spine

Move and Measure

- Elbows straight, thumbs facing forward, feet shoulders width apart
  - Bring arms all the way up high up to ears – flexion (coracobrachialis, pectoralis major, anterior deltoid)
  - Slowly down, and follow through movement to back – extension (latissimus dorsi, teres major, posterior deltoid, pectoralis major)
- Thumbs out to side
  - All the way up to ears – abduction (deltoid, supraspinatus, pectoralis major)
  - All the way back down – adduction (pectoralis major, coracobrachialis, latissimus dorsi, teres major)
- Elbows tight at side and rotate hands out either side – external rotation (infraspinatus, teres minor, posterior deltoid)

REPEAT FROM BACK

- Right thumb up centre of back – internal rotation (subscapularis, latissimus dorsi, teres major, deltoid, pec. Major)
  - Repeat with left side

Forward flexion = deltoid, pec major
Extension = deltoid
Abduction = deltoid (supraspinatus and trapezius)
Adduction = pec major, latissimus dorsi
External rotation (lateral) = infraspinatus
Internal rotation = subscapularis

Special Shoulder Tests	
Hawkins-Kennedy Test ?supraspinatus impingement Sensitivity 90%, specificity 30%	Patient stands and places arm at a 90° on top of the examiners arm, examiner them forcibly medially rotates the shoulder. Helpful in RULING OUT impingement; +ve test is meaningless
Drop Arm Test ?supraspinatus tear Sensitivity 10%, specifity 100%	Examiner abducts patient arm and then asks them to adduct. Test is +ve = high chance there is a tear; -ve test is not useful
Empty Can Test ?supraspinatus tear Sensitivity 18%, specificity 100%	Patient tested at 90° elevation in scapula plane & full internal rotation (empty can). Patient resists downward pressure exerted by examiner. Test is +ve = high chance there is a tear; -ve test is not useful
Apprehension ?glenohumeral joint anterior instability Sensitivity 69%, specificity 100%	Patient lying on bed – abduct shoulder, flex elbow and externally rotate humerus until patient asks to stop – then apply pressure to posterior aspect of humeral head. Test is +ve = instability; -ve test = possibly no instability

Apprehension	Glenohumeral joint stability +ve = likely -ve = possibly not
Hawkins Kennedy	Supraspinatus impingement +ve = meaningless -ve = unlikely RULE OUT
Drop arm and Empty can	Supraspinatus tear +ve = very likely -ve = meaningless

MUSCULOSKELETAL EXAMINATION

FOCUSSED KNEE

INTRODUCE	EXPLAIN	CONSENT	WASH HANDS

Position: patient initially standing, later lying on bed

'If you experience any pain, discomfort, if you feel uncertain/unsteady or need me to repeat anything let me know'

Vital Signs

- BP
- ↑ HR and RR (pain, infection)
- ↑Temp (infection)

General Inspection (STANDING)

- Muscle bulk, symmetry
- Position of patella
- Ask patient to walk and turn around – note symmetry/gait deformities

Move

- Feet shoulders width apart
  - ½ squats (patellofemoral joint, partial flexion knee)
  - Full squat - raise heel or keep flat (knee joint proper, flexion knee)

ASK PATIENT TO LIE DOWN

Inspection

- Scars, bruising, swelling, erythema
- Knee deformity

Palpation

- Temperature
- Patella-femoral joint movement (for crepitus) – passive flexion and extension knee
- Patella, patella ligament, tibial tuberosity, anterior joint line
- Medial and lateral tibial condyles
- Medial collateral ligament and anserine bursa, medial epicondyle
- Fibular head, lateral collateral ligament, lateral epicondyle
- Iliotibial band, quadriceps tendon

Move and Measure

- Push legs into bed – full extension (assess muscle bulk and tone)
  - Knee extension – quadriceps femoris
  - Knee flexion – short head biceps, hamstrings (semitendinosus, semimembranosus, long head biceps)
- Slide heels up to bottom – knee flexion and extension (symmetry)

Special Knee Tests	
Lachman Test ?anterior cruciate ligament tear Sensitivity >95%, no reliable specificity	Patient supine – place a small bolster under the knee and use hand closest to the patient's thigh to stabilize the distal femur (not the knee) against the bed. Other hand then grasps proximal end of the patient's tibia from the medial aspect w thumb overlying the tibial tuberosity – perform anterior and posterior movements of the proximal tibia. Test is –ve = unlikely ACL tear; +ve test is meaningless
Valgus and Varrus Test ?collateral ligament tears Sensitivity 90%, no reliable specificity	Hold knee at 30 degree flexion, and perform valgus and varrus movements Test is –ve = unlikely collateral ligament tear; +ve test is meaningless
Thessaley Test ?mensical pathology/tear Sensitivity 92%, specificity 97%	- Patient stands w feet shoulder width apart – examiner supports - Patient flexes unaffected knee off ground, affected knee is flexed 5 degrees and locked in that position – patient then rotates the knee joint (grinding the joint) – if experience pain point to site o Then flex affected knee to 20 degrees and lock and repeat - Pain localized to medial or lateral joint line is suggestive of a tear VERY RELIABLE AND VALID TEST

Lachman	Anterior cruciate ligament tear -ve = unlikely
Varus valgus	Collateral ligament tear Valgus = medial collateral Varus = lateral collateral -ve = unlikely
Thessaly	Meniscal pathology +ve = quite likely -ve = unlikely VERY GOOD TEST

MUSCULOSKELETAL EXAMINATION

GALS SCREENING TEST

INTRODUCE	EXPLAIN	CONSENT	WASH HANDS

'If you experience any pain, discomfort, if you feel uncertain/unsteady or need me to repeat anything let me know'

Vital Signs

Gait

- Walk few steps, turn briskly and walk back (symmetry, smoothness, ability turn quickly)
- Anatomical position (abnormalities muscle = bulk; spine = spinal curvature; limbs/joints = swelling, erythema)

Arms

- Hands behind head with elbows pulled back
  - Abduction shoulder (adduction shoulder reverse), external rotation shoulder, flexion elbow (extension elbow reverse), retraction scapula
- Run thumb up centre of back one at a time
  - Glenohumeral joint internal rotation, flexion elbow
- Elbows locked against sides rotate forearms outwards as far as possible
  - Glenohumeral joint external rotation, flexion elbow
- Elbows locked supinate then pronate hands
  - ROM proximal (and distal) radioulna joint
- Grip strength, abduction and adduction fingers, metacarpophalangeal squeeze test, opposition thumb

Legs

- 6 half squats (30^0 flexion knee)
  - Partial flexion hip, partial flexion knee, patellofemoral function, dorsiflexion ankle
- Full squats as far down as possible - raise heel of floor and lower heels onto floor just prior to standing
- Flexion hip (extension hip reverse), flexion knee (extension knee reverse), dorsiflexion ankle (plantar flexion ankle reverse), extension metatarsophalangeal joint (flexion reverse)
- Feet
- If unable to do squats
  - Knee
    - Slide heels to buttock (flexion knee, crepitus, patellar region, evidence effusion, patellofemoral tenderness)
    - Straighten legs and push into bed (knee flexion)
  - Hip
    - Internal and external rotation (flex hip to 90^0 and knee to 90^0 then rotate foot towards contralateral shoulder = external; towards ipsilateral shoulder = internal)

Spine

- Bend forward and touch toes slowly with knees straight
  - Lumbosacral flexion, thoracolumbar flexion
- Extend backwards keeping knees straight o
  Lumbosacral extension
- Slide hand down lateral aspect of thigh on each side
  - Lumbosacral lateral flexion
- Flexion (chin to chest)
- Extension (look back and at ceiling)
- Lateral flexion – left and right (ear to shoulder)
- Rotation – right and left (look over shoulder)

RENAL EXAMINATION

CHRONIC RENAL FAILURE

INTRODUCE	EXPLAIN	CONSENT	WASH HANDS

Position: sitting on the edge of the bed with shirt off (will have to lie flat for abdo)

General Inspection

- Body habitus – fluid balance, sallow complexion (uraemic tinge)
- Mental state (drowsiness, coma)
- Hyperventilation (acidosis), hiccups (uraemia)
- Hydration, subcutaneous nodules (calcium phosphate deposits), uraemic fetor

Vital Signs

- BP – hypertension, postural hypotension
- HR, RR – can be ↑
- Temp

Hands

- Palmar crease pallor
- Nails: leukonychia, Meuhrke's nails (hypoalbuminaemia), Mees' lines (white line), half-and-half nails (distal brown arc), Beu's lines
- Asterixis, myopathy

Arms

- Scars of wrist and forearm, AV fistulae/shunts
- Scratch marks, excoriations, bruising, skin pigmentation
- Peripheral neuropathy

Face

- Rash (lupus, vasculitis etc)
- Eyes: conjunctival pallor, scleral icterus, band keratopathy, fundoscopy (DM and HTN retinal changes)
- Mouth: dryness, ulcers, uraemic fetor, gingival hyperplasia, infection (thrush)

Neck

- Scars: previous vascath insertion, jugular vein puncture or parathyroidectomy
- JVP, carotid bruits

Chest

- CVS: CCF, hyptertension, pericarditis, cardiac tamponade - heaving apex
- RS: infection, pulmonary oedema

Abdomen

- Inspection: tenckhoff catheter, scars (nephrectomy, renal transplant, peritoneal dialysis)
- Palpate: renal masses, kidneys (transplant), bladder, hepatomegaly, lymph nodes, AAA
- Percuss: ascites, bladder enlargement
- Auscultate: renal bruits
- DRE and pelvic examination (prostatomegaly, frozen pelvis, bleeding), scrotal mass, genital oedema
- Back: nephrectomy scar, bony tenderness, sacral oedema, Murphy's kidney punch

Legs

- Oedema (nephritic syndrome, CCF), bruising/purpura, livedo reticularis, pigmentation, scratch marks, vascular access, neuropathy, PVD, gouty typhi
- Peripheral neuropathy and myopathy

Urinalysis: specific gravity, pH, glucose (DM), blood (nephritis/infection/stone), protein (nephritis)

Other: BP (lying and standing), fundoscopy (HTN and DM changes), rash, livedo reticularis

BREAST EXAMINATION

INTRODUCE	EXPLAIN	CONSENT	WASH HANDS

3 parts: checking lymph nodes, visually inspecting breast w arm movements, lying down and palpating breasts

Ask if there are any particular areas of concern, and note to the patient that it may feel uncomfortable but should not be painful

Position: patient undressed and draped, initially sitting on side of bed

Lymph Nodes

- Palpate lymph nodes
- Supraclavicular, infraclavicular, pectoral, subscapular, central and lateral
- Enlargement, tenderness, mobility, texture

Inspection Breasts

I am now going to inspect your breasts and look for any changes in skin, please lower your gown

- At rest, hands on hips, roll shoulders forwards and back, arms above head
- Scarring, lumps, traction on skin, pulling or inversion of nipples, Peau d'orange appearance

Well Women's Check

I hear you have come in for a Well Women's check – have you had one before?
So it involves three components - i) breast examination ii) pap smear and iii) pelvic examination

The breast examination has 3 parts: first I will check your lymph nodes, then visually inspect the breasts with some arm movements, and then I will get you to lie down on the bed and I will palpate the breast tissue

Pap smear involves insertion of speculum into the vagina to site the cervix and collect cells

Bimanual pelvic examination involves insertion 2 gloved fingers into the vagina to check the cervix and ovaries

Points to mention:

- Breast: self-checking (after period for menstruating women, first day of the month otherwise), mammogram every 2 years aged 50-69 years
- Pap smear: every 2 years, pap smear results will return in 10 working days, pap smear registry will send out a letter to remind them when to next have a pap smear (opt out system), mild

PELVICEXAMINATION

INTRODUCE EXPLAIN CONSENT WASH HANDS

Inform – pelvic examination involving pap smear and bimanual pelvic examination
Pap smear involves insertion of speculum into the vagina to site the cervix and collect cells
Bimanual pelvic examination involves insertion 2 gloved fingers into vagina to check for abnormalities cervix and ovaries

You may experience some discomfort, but if it is painful at any point please let me know and we can stop the examination.

Position: patient undressed and draped, laying on the bed **Preparation:**

wash hands, glove, set up equipment, lubricate speculum **Inspection**

- *Can I please get you to move your feet towards your bottom and relax your knees then remove the drape*
- Inspect external genitalia

Palpation

- *I will now insert the speculum so I can see your cervix and obtain a pap smear sample*
- Touch the inner thigh, part the labia
- Insert speculum completely before opening and locking, collect samples, release screwholding speculum open then remove 1cm before letting leaver close as removing speculum
- Note position cervix (prolapsed, normal), cervix parous or nulliparous, cervical or vaginal vault discharge, cervical lesions, atrophy vagina
- *I will now insert my gloved fingers into the vagina*
- Palpate cervix – size, contour, mobility, fornix for adnexa
- *Everything appears healthy and normal I will leave you so you may get dressed and return to answer any questions*

Palpation Breasts

Now I am going to examine your breasts

- Palpation breast light and deep pressure in systematic vertical strip pattern
- Patient lying down, arm overhead with pillow under shoulder for large breasted women
- Consistency breast tissue, tenderness, nodules (location, size, shape, consistency, delimitation, tenderness, mobility)
- Palpate under nipple for lumps
- Nipple discharge (press on either side nipple)

Everything appears healthy and normal OR I have identified changes/lump in breast that requires further evaluation

INGUINAL EXAMINATION

INTRODUCE EXPLAIN CONSENT WASH HANDS

Inform – inguinal examination is looking for any abnormality in the groin & include reasons for examination

You may experience some discomfort, but if it is painful at any point please let me know and we can stop the examination.

Position: patient undressed and draped, initially sitting on side of bed

Inspection

- *I am going to look for any abnormality in your groin and then palate. I will ask you to cough to test for a hernia*
  - Asymmetry, swelling, scars from previous surgery, discolouration
- *Could you please cough*
  - Cough with inspection then cough with palpation inguinal area
  - Positive cough impulse, orient to type hernia, compare with opposite side, auscultate bowel sounds, determine if hernia reducible
- *Could you please stand and I will again look and palpate for a hernia*
  - Cough with inspection

Palpation

- *I am going to palpate for a hernia at the top of your leg. It will involve pushing back your scrotum. If it is uncomfortable please let me know and I will stop.*
  - Palpate at bottom of scrotum and push back along spermatic cord angling towards superficial inguinal ring and palpate again for cough impulse at superficial inguinal ring

Hernia

1. Direct inguinal hernia = anterior bulging through defect in abdominal wall Hasselbach's triangle
2. Indirect inguinal hernia = through internal inguinal ring into inguinal canal and scrotum
3. Femoral hernia = below and lateral to pubic tubercle

MINI MENTAL STATE EXAM (MMSE)

INTRODUCE EXPLAIN CONSENT WASH HANDS

General Appearance

- Is the patient well?
- Is the patient alert?
- Is the patient oriented? – can you tell me your name, the date and where weare?

Vital Signs

Orientation

- Orientation to time **5 MARKS**
  - What is the year?
  - What is the month?
  - What is the day?
  - What is the date?
  - What is the season?
- Orientation to place **5 MARKS**
  - Where are we right now?
  - What country?
  - What state?
  - What town/region?
  - What suburb?

Registration

- Name 3 common objects – I am going to tell you 3 objects that you need to remember – apple, penny, table
- Can you please repeat those objects now? **3 MARKS**

Attention

- Can you please spell the word WORLD backwards? **5 MARKS**
- Alternatively serial 7s – can you please count back from 100 in 7s?

Recall

- Can you please tell me those 3 objects I asked you to remember before? (apple, penny, table) **3 MARKS**

Language

- I am going to point to 2 objects (pen and watch) can you please tell me what they are? **2 MARKS**
- Can you please say 'no ifs, ands or buts' for me? **1 MARK**
- Can you please read this instruction for me and follow it? CLOSE YOUR EYES **1 MARK**
- Can you follow these 3 instructions (pick up the paper, fold it in half, place it on the desk)? **3 MARKS**
- Can you please copy this simple drawing? (2 pentagons interlocked to form diamond) **1 MARK**

TOTAL SCORE MMSE = /30

- Score <24 = cognitive impairment
- 21-24 = mild disability
- 10-20 = moderate disability
- <10 = severe disability

SYSTEMS REVIEW QUESTIONS

Cardiovascular
- Chest pain, angina
- SOBOE, PND, orthopnea
- Syncope
- Palpitations
- Peripheral oedema
- Calf pain, fatigue

Respiratory
- SOB
- Cough, sputum, hemoptysis
- Fevers, chills, night sweats
- Stridor, wheeze

Gastrointestinal
- Dysphagia (solids/liquids)
- Heartburn/ulcers - indigestion, heartburn
- Nausea and vomiting
- Abdominal pain, distention, bloating
- Changes bowel habit - pain, blood, mucous

Haematological
- Anaemia - weakness, tiredness, dyspnea, fatigue, postural dizziness
- Bleeding - menstrual, GI, dental extraction
- Easy bruising, excessive bleeding when cut yourself
- Fevers, chills, rigors
- Lymphadenopathy
- Bone pain
- Weight loss
- Infection

Genitourinary
- Hesitancy
- Stream
- Colour, smell, haematuria
- Polyuria, oliguria
- Burning or dysuria
- Dribbling
- Frequency and nocturia

Neurological
- Headaches
- Memory problems, trouble concentrating
- Fits, feinting, blackouts
- Weakness, numbness, clumsiness arms/legs
- Head injury
- Feel sad or depressed

Endocrine
- Appetite, weight
- Lump neck
- Sweating, hair distribution
- Lethargy
- Skin pigmentation
- Loss libido, erectile dysfunction, menstruation
- Bowels, polyuria

Musculoskeletal
- Painful or stiff joints
- Erythema, swelling, pain joint
- Dry or red eyes
- Back or neck pain

HISTORY BOXES FROM TALLEY

CARDIOVASCULAR HISTORY

Angina History

- Can you tell me what the pain or discomfort is like? Is it sharp or dull, heavy or tight?
- When do you get the pain? Does it come out of the blue, or come on when you do physical things? Is it worse if you exercise after eating?
- How long does it last?
- Where do you feel it?
- Does it make you stop or slow down?
- Does it go away quickly when you stop exercising?
- Is it coming on with less effort or at rest? – Unstable symptoms
- Have you had angina before, and is this the same?

Palpitations History

- Is the sensation one of the heart beating abnormally, or something else?
- Does the heart seem fast or slow? Have you counted how fast? Is it faster than it ever goes at any other times eg. Exercise?
- Does the heart seem regular or irregular – stopping and starting? If it is irregular, is this the feeling of normal heart beats interrupted by missed or strong beats – ectopic beats; or is it completely irregular? – Atrial fibrillation
- How long do the episodes last?
- Do the episodes start and stop very suddenly? – SVT
- Can you terminate the episodes by deep breathing or by holding your breath? – SVT
- Is there a sensation of pounding in your neck? – some types of SVT
- Has an episode ever been recorded on an ECG?
- Have you lost consciousness during an episode? – ventricular arrhythmias
- Have you had other heart problems such as heart failure or a heart attack in the past? – ventricular arrhythmias
- Is there heart trouble of this sort in the family?

?PVD History

- Have you had problems with walking because of pains in the legs?
- Where do you feel the pain?
- How far can you walk before it occurs?
- Does it make you stop?
- Does it go away when you stop walking?
- Does the pain ever occur at rest? – Severe ischaemia may threaten the limb
- Have there been changes in the colour of the skin over your feet or ankles?
- Have you had any sores or ulcers on your feet or legs that have not healed?
- Have you needed treatment of the arteries of your legs in the past?
- Have you had diabetes, high BP, or problems with strokes or heart attacks in the past?
- Have you been a smoker?

CVD Risk Factors

- Have you had angina or a heart attack in the past?
- Do you know what your cholesterol level is – before/after treatment?
- Are you a diabetic?
- Have you had high BP and has it been treated?
- Are you now or have you been a smoker? How long since you stopped?
- Has anyone in the family had angina or heart attacks? Who? How old were they?
- Have you had kidney problems?

HTN History

- Do you use much salt in your diet, or eat salty prepared or snack foods?
- Have you put on weight recently?
- How much alcohol do you drink?
- What sort of exercise do you do and how much?
- Have you had any kidney problems?

- Do you take your blood pressure at home? What readings do you get?
- Are you taking any blood pressure tablets and do these cause you any problems?

Murmur History

- Has anyone noticed this murmur before? Were any tests done?
- Did you have rheumatic fever as a child?
- Have you been told you need antibiotics before dental work or surgical operations?
- Have you become breathless when you exert yourself?
- Have you had chest tightness during exercise? – aortic stenosis
- Have you had dizziness or a blackout during heavy exercise? – severe aortic stenosis
- Have you been breathless lying flat? – heart failure complicating valve disease

RESPIRATORY HISTORY

Cough History

- How long have you had the cough?
- Do you cough up anything? What? How much?
- Have you had sinus problems?
- Is the sputum clear or discoloured? Is there any blood in the sputum?
- Have you had high temperature?
- Does coughing occur particularly at night? – Acid reflux, Asthma
- Have you become short of breath?
- Have you had lung problems in the past?
- Have you been a smoker? Do you still smoke?
- Have you noticed wheezing? – Asthma, chronic obstructive pulmonary disease (COPD)
- Do you take any tablets? – ACE inhibitors

SOB History

- How long have you been short of breath? Has it come on quickly?
- How much exercise can you do before your SOB stops you or slows you down? Can you walk up a flight of stairs?
- Have you been woken at night by breathlessness or had to sleep sitting up? PND and orthopnoea
- Have you had heart or lung problems in the past?
- Have you had a temperature?
- Do you smoke?
- Is there a feeling of tightness in the chest when you feel breathless? – Angina
- Do you get wheezy in the chest? Cough?
- Is the feeling really one of difficulty to get a satisfying breath? – Anxiety
- Is it painful to take a big breath? – Pleurisy or pericarditis
- Did the shortness of breath come on very quickly or instantaneously? – Pulmonary embolus (very quick onset) or pneumothorax (instantaneous)

GASTROINTESTINAL HISTORY

Recurrent vomiting history

- How long have you been having attacks of vomiting (distinguish acute from chronic)?
- Does the vomiting occur with nausea preceding it, or without any warning?
- Is the vomiting usually immediately after a meal or hours after a meal?
- Do you have vomiting early in the morning or late in the evening?
- What does the vomit look like? Is it bloodstained, bile-stained or faeculent? – GI bleeding or bowel obstruction
- Do you have specific vomiting episodes following by feeling completely well for long periods before the vomiting episode occurs again? – cyclical vomiting syndrome
- Is there any abdominal pain associated with the vomiting?
- Have you been losing weight?
- What medications are you taking?
- Do you have worsening headaches? – neurological symptoms suggest a central cause

GORD History

- Do you have heartburn (a burning pain under the sternum radiating up towards the throat)?
- How often does this occur? - >1 times/wk suggests GORD
- Does your heartburn occur after meals or when you lean forward or lie flat in bed?
- Does the pain radiate across the chest down the left arm or into the jaw? –MI
- Is the pain relieved by antacids or OTC acid-suppressing medicines?
- Do you experience suddenly feeling bitter tasting fluid in the mouth? – Acid regurgitation
- Have you experienced the sudden appearance of a salty tasting or tasteless fluid in the mouth? – Waterbrash (PUD/oesophagitis)
- Have you had trouble swallowing? – Dysphagia
- Have you been troubled by a cough when you lie down?

Dysphagia

- Do you have trouble swallowing solids, liquids or both? – solids and liquids suggest motor problem (achalasia)
- Where does the hold-up occur (please point)? – oesophageal carcinoma
- Is the trouble swallowing intermittent or persistent? – intermittent suggest eosinophilic oesophagitis
- Has the problem been getting progressively worse?
- Do you cough or choke on starting to swallow (odynophagia)?
- Do you have any heartburn or acid regurgitation?
- Have you been losing weight?

Diarrhoea History

- How many stools a day do you pass now normally?
- What do the stools look like (form – loose or watery)?
- Do you have to race to the bathroom to have a bowel movement? – Urgency in colonic disease
- Have you been waken from sleep during the night by diarrhoea? – Organic cause likely
- Have you seen any bright-red blood in the stools or mucus or pus? – Colonic disease
- Are you passing large volumes of stool every day? – Small bowel disease
- Are your stools pale, greasy, smelly and difficult to flush away (steatorrhoea)? Have you seen oil droplets in the stool? – Pancreatic disease
- Have you had problems with leakage of stool (incontinence)?
- Have you lost weight? – Cancer, malabsorption
- Have you had any abdominal pain or vomiting?
- Have you had treatment with antibiotics recently?
- Have you had any recent travel? Where to?
- Have you a personal history of IBD or prior gastrointestinal surgery?
- Have you any history in the family of celiac disease or IBD?
- Have you had any problems with arthritis? – IBD, Whipple's disease

- Have you had recent fever, rigors or chills (eg. Infection/lymphoma)? Have you had frequent infections? – Immunoglobulin deficiency

Constipation

- How often do you have a bowel movement?
- Are your stools hard or difficult to pass?
- What do the stools look like (stool form eg. Small pellets)?
- Do you strain excessively on passing stool?
- Do you feel there may be a blockage at the anus area when you try to pass stool?
- Do you ever press your finger in around the anus (or vagina) to help pass stool?
- Has your bowel habit changed recently?
- Any recent change in your medications?
- Any blood in the stools?
- Any abdominal pain?
- Recent weight loss?
- Do you ever have diarrhoea?
- Do you have a history of colon polyps or cancer? Any family hx of colon cancer?

Haematemesis History

- Was there fresh blood in the vomitus? Or was the vomitus coffee-grain stained?
- Have you passed any black stools or blood in the stools?
- Before any blood was seen in the vomitus, did you experience intense retching or vomiting? – Mallory-Weiss tear
- Have you been taking aspirin, NSAIDs or steroids?
- Do you drink alcohol?
- Have you ever had a peptic ulcer?
- Have you lost weight?

Jaundice History

- Is your urine dark? Are your stools pale? – Obstructive jaundice
- Do you have any skin itching (pruritis)? – Obstructive
- Have you had any fever?
- Have you had a change in your appetite or weight? – Malignancy
- Have you had any abdominal pain or change in bowel habit?
- Have you had any vomiting of blood or passage of dark stools?
- Do you drink alcohol? How much? How long? CAGE.
- Have you ever used IV drugs?
- Have you ever had a blood transfusion?
- Have you started any new medications recently?
- Have you had any recent contact with patients with jaundice or liver problems?
- Any history of recent high-risk sexual behaviours?
- Have you travelled overseas to areas where hepatitis A is endemic
- Have you been immunised against Hepatitis B?
- Any history of IBD?
- What is your occupation (contact with hepato-toxins)?
- Is there any family history of liver disease?

GENITOURINARY HISTORY

Renal Disease History

- How did your kidney problems begin? Have you had tiredness, the need to pass urine at night (nocturia) or loss of appetite?
- Was the kidney trouble thought to be brought on by any medication you were taking (NSAIDs, ACE-inhibitors/ARBs, or contrast)
- Were you told there was inflammation in the kidneys (glomerulonephritis) or protein in the urine?
- Have you had any kidney infections recently or as a child?
- Have you had kidney stones or urinary obstruction?
- Have you passed blood in the urine? – Urinary tract malignancy
- Have you had a biopsy of your kidney? Do you know the result?
- Have you had diabetes or high BP?
- Have you had cardiovascular disease or PVD?
- Have you had kidney surgery or removal of a kidney, or have you been told you only have one functioning kidney?
- Is there a history in the family of enlarged kidneys and high BP? – Polycystic kidneys
- Have you had problems with rashes or arthritis? – Scleroderma or SLE
- Have you had problems with swelling or SOB? – Fluid retention
- Have you been told how bad your kidney function is and whether you may need dialysis one day?
- Are you taking medications to help the kidneys function?
- What tablets and medications (including OTC, herbal remedies) are you taking?

Dialysis History

- What fluid restriction have you been recommended?
- Have phosphate-binding drugs been prescribed? When do you take these relative to meals?

- Do you use haemodialysis or peritoneal dialysis? Do you do this at home? How many times a week?
- Have you had abdominal pain or fever recently? – Peritonitis related to peritoneal dialysis
- Have there been any problems with haemodialysis, such as low BP, or with the fistula used for haemodialysis? Have there been any problems with peritonitis with peritoneal dialysis?
- How much weight do you gain between each haemodialysis?
- Do you still pass any urine? If so, how much?
- Are you on a renal transplant list, or have previously had a transplant?
- Do you follow recommended dietary restrictions?
- What other medications do you take?
- Have you had heart or blood vessel problems?
- Have you had overactive parathyroid glands or parathyroid surgery?

ENDOCRINE HISTORY

Hyperthyroidism History

- Have you any history of thyroid problems?
- Have you a family history of thyrotoxicosis? – familial incidence of Graves disease and assoc. auto-immune conditions such as vitiligo, Addison's disease, pernicious anaemia, T1DM, myasthaenia gravis and premature ovarian failure
- Have you taken amiodarone or thyroxine?
- Have you had recent exposure to iodine? – iodinated X-ray contrast
- Have you had palpitations? – Thyrotoxicosis can present with AF which may precipitate HF
- Have you noticed insomnia, irritability or hyperactivity?
- Have you had loss of weight, diarrhoea or increased stool frequency, increased sweating or heat intolerance?
- Have you had muscle weakness? – Proximal myopathy is common and the patient may have noticed difficulty getting out of a chair
- Have you had eye problems: double vision, grittiness, redness or pain behind the eyes?

Hypothyroidism History

- Have you found cold weather more difficult to cope with recently?
- Have you had problems with constipation?
- Have you gained weight?
- Have you noticed that your skin has become dry?
- Do you think your memory is not as good as it was? Have you felt depressed?
- Do you think your voice has become hoarse? – Hypothyroid speech 1/3 of patients
- Have you noticed swelling of your legs?

Panhypopituitarism History

- Have you had problems with lethargy, weakness, fatigue or weight loss or poor appetite? – Adrenocorticoid deficiency
- Have you gained weight, found cold weather more interolable or had constipation? – TSH deficiency
- (men) Have you noticed reduced sexual interest (libido), reduced muscle strength, erectile dysfunction or had problems with infertility? - FSH deficiency

- (women) Have you had less bleeding during menstruation? – Oligomenorrhoea due to FSH deficiency
- Have you noticed reduced exercise ability and energy? – GH deficiency in adults
- Have you had headaches or visual disturbance? – Pituitary enlargement

Cushing's syndrome History

- Have you gained a lot of weight recently? How much?
- Do you bruise easily?
- Has your skin become thin?
- Have you had problems with acne?
- Have you felt agitated and been unable to sleep?
- Have you had problems with weakness of your muscles or difficulty getting up out of chairs? – Proximal myopathy
- Have you had problems maintaining erection (men) or had amenorrhoea (women)?
- Have you been diagnosed with diabetes?

Hyperparathyroidism History

- Have you had kidney stones?
- Have you had any fractures?
- Have you been troubled by abdominal pain? Constipation?
- Have you been depressed or had hallucinations? – Psychiatric disorders
- Have you had episodes of confusion, irritability, extreme tiredness or even unconsciousness? – Neurological symptoms

Hypocalcaemia History

- Have you recently had surgery to remove the parathyroid glands?
- Have you had tingling around the mouth or in the fingers?
- Have you had muscle cramps?
- Have you had seizures?

Diabetes History

- What was your age at the time the diabetes was diagnosed?
- Did you require insulin from the start?

- What was the problem that led to diagnosis? – Polyuria, thirst, weight loss, recurrent skin infections, screening assessment
- What previous and current drug treatment are you taking for diabetes?
- What diet has been prescribed? What do you understand about your diabetic diet?
- What blood sugar testing do you do? What are the usual results?
- Have you had any problems with hypoglycaemia (treatment-induced low blood sugar)? Have you had episodes of sweating, confusion, malaise or unconsciousness?
- Do you know what action should be taken if these symptoms occur? – check BSL, take glucose tablet, go to hospital
- Have you had keto-acidosis and needed admission to hospital? – polyuria, dehydration, confusion, unconsciousness
- Have you had complications of diabetes – eyes, nerves, blood vessels or kidneys?
- What regular testing has been performed for these problems?
- How do you and your family cope with this chronic condition?
- Have you been able to work?

NEUROLOGICAL HISTORY

Headache History

- What is the pain like – dull, sharp, throbbing or tight?
- Where do you feel it – at the front or back, on one side of the face?
- How severe is it and how long does it last?
- Has it begun very suddenly and severely? – SAH
- Do you get any warning that it is about to start – eg. Flashing lights or zigzag lines in your vision? – Migraine
- Is it assoc. w sensitivity to light (photophobia)? – Migraine
- Do you feel drowsy or nauseated? – raised ICP
- Is the pain on one side over the temple and have you had any blurred vision? – Temporal arteritis
- Is the pain worst over your cheek bones? – Sinusitis
- Are the attacks likely to occur in clusters and associated w watering of one eye? – Cluster headache
- Is there a prolonged feeling of tightness over the head but not other symptoms? – Tensions headache
- Did you drink large amounts of alcohol last night? – Hangover

Syncope/Dizziness History

- Have you lost consciousness completely? How long for?
- Do you black out or feel dizzy when you stand up quickly? – postural hypotension
- How often have episodes occurred?
- Was the sensation more one of spinning? – Vertigo
- Did the episode occur during heavy exercise or when you got up to pass urine at night? o

    Exercise – LV outflow tract obstruction (aortic stenosis)

    - Pass urine at night – micturition syncope
- Have you injured yourself?

- Do you get any warning? – a feeling of nausea and being in a stuffy room suggests a vasovagal episode; a strange smell or feeling of déjà-vu suggests an aura and therefore a seizure
- Have you passed urine during the episode? – seizure
- Have you ever bitten your tongue? – seizure
- Has anyone seen an episode and noticed jerking movements? – seizure but also cardiac syncope
- Do you wake up feeling normal or drowsy?
    - Normal – cardiac syncope
    - Drowsy – seizure
- What medications are you taking – any antihypertensives, cardiac antiarrhythmics or anti-epileptic drugs?

Muscle Weakness History

- Have you felt weakness on both sides of the body? – suggests spinal cord disease, myopathy or myasthaenia gravis
- Is the weakness just on one side of the body or face? – TIA or stroke
- Has the weakness affected just an arm or leg or part of a limb? – peripheral neuropathy or radiculopathy, stroke or MS
- Have you had trouble getting up from a chair or brushing your hair or lifting your head? – proximal muscle weakness (myasthaenia gravis, diabetic amyotrophy, polymyositis)
- Have you had trouble swallowing or difficulty speaking? – myasthaenia gravis, polymyositis
- Have you noticed double vision? – Myasthaenia gravis, CN mononeuritis multiplex
- Are you taking any medications? – steroid-induced proximal myopathy
- Have you had problems with your neck or back or with severe arthritis? –radiculopathy
- Have you had a cancer diagnosed at any stage? – paraneoplastic, Eaton-Lambert syndrome
- Is there any problem like this in the family? – familial myopathy, Charcot-Marie-Tooth disease
- Have you had HIV Infection?
- Have you ever been diagnosed with MS?
- Are you a diabetic? – mononeuritis multiple, amyotrophy

JAMES COOK UNIVERSITY
MEDICAL STUDENTS ASSOCIATION

GOOD LUCK FOR YOUR EXAMS

FROM JCUMSA